



Classification of premolars sagittal root position and angulation for immediate implant placement: a cone beam computed tomography study

Yalin Zhan, PhD,^{a,b,c,d,e,f} Miaozhen Wang, DDS,^{a,b,c,d,e,f} Xueyuan Cheng, BDS,^{a,b,c,d,e,f} and Feng Liu, DDS^{a,b,c,d,e,f}

Objectives. Sagittal root position (SRP) and buccal plate thickness are important considerations in implant treatment planning. The objective of this study was to classify the relationship of the SRP and angulation to the osseous housing to assist treatment plan making for immediate implant placement in the premolar region.

Study Design. We classified the SRP and angulations of the maxillary and mandibular premolars and measured the buccal plate thickness of 150 patients using cone beam computed tomography to support clinical decision making.

Results. Regarding SRP types, 41.67%, 51.83%, 3.67%, and 2.83% of maxillary premolars and 84.33%, 15%, 0%, and 0.67% of mandibular premolars were classified as types B, M, L, and N, respectively. In terms of angulation, 20.83%, 46%, 32.17%, and 1% of maxillary premolars and 2%, 5.33%, 36.67%, and 56% of mandibular premolars were grouped into classes 1, 2, 3, and 4, respectively. The buccal bone thickness at most locations in premolar regions was <1 mm.

Conclusions. The classification of SRP and angulation will assist in treatment plan making for immediate implant placement in the premolar region. (Oral Surg Oral Med Oral Pathol Oral Radiol 2023;135:175–184)

Replacement of a hopeless tooth by immediate implant placement (IIP) is a reliable procedure.¹ Sagittal root position (SRP) relative to the osseous housing is crucial for determining the feasibility of IIP and can be estimated using cone beam computed tomography (CBCT).²

The esthetic compromise manifesting in mid-buccal and interdental recession and loss of buccal contours is a challenge in IIP.³ Successful IIP depends on the implant position in 3 dimensions, tissue dimensions and morphology, and primary stability.⁴ An appropriate preoperative assessment promotes implant osseointegration and esthetics.

Previous studies have classified the SRP of the maxillary anterior teeth and measured buccal plate thickness to assist treatment planning for IIP.^{2,5-9} At present, the broad region of interest in terms of esthetics comprises the premolars. To date, no data are available on the root position or angulation to the alveolar bony housing in the premolar region.

In this article, we classify the relationship of the SRP and angulation to the osseous housing and evaluated the buccal plate thickness of premolars using CBCT. Then, we discuss the clinical implication of these anatomic variables.

MATERIALS AND METHODS

The protocol was reviewed and approved by the Ethics Committee of Peking University School and Hospital of Stomatology (PKUSSIRB-202054033). This study was conducted in accordance with the Declaration of Helsinki. All of the patients involved in this study provided their informed consent before inclusion in this study.

Subject selection

The CBCT images obtained at the Oral Radiology Clinic in the First Clinical Division of the Peking University School and Hospital of Stomatology from January 2016 to November 2019 were reviewed. We enrolled 69 male and 81 female patients aged 18 to 44 years in this study according to the following criteria: ≥ 18 -years-old at the time of the CBCT scan, all maxillary and mandibular premolar teeth present, and 2 occluding molars in each quadrant. The exclusion criteria were a history of periodontitis, orthodontic therapy, or periodontal

^aFirst Clinical Division, Peking University School and Hospital of Stomatology.

^bNational Center of Stomatology.

^cNational Clinical Research Center for Oral Diseases.

^dNational Engineering Research Center of Oral Biomaterials and Digital Medical Devices.

^eBeijing Key Laboratory of Digital Stomatology.

^fResearch Center of Engineering and Technology for Computerized Dentistry Ministry of Health & NMPA Key Laboratory for Dental Materials.

Corresponding author: Feng Liu E-mail address: Dentistliufeng@126.com

Received for publication Apr 8, 2022; returned for revision May 14, 2022; accepted for publication May 29, 2022.

© 2022 Published by Elsevier Inc.

2212-4403/\$-see front matter

<https://doi.org/10.1016/j.oooo.2022.05.013>

Statement of Clinical Relevance

The classification of sagittal root position and angulation of premolars can be used in treatment plan making for immediate implant placement and improve interdisciplinary communication during the planning of immediate implant placement.

surgery; radiographic evidence of infection; history of trauma to the maxillary and mandibular premolar dentition; obvious anatomic abnormalities including buccal ledging and exostoses; severe crowding; and severe root resorption. The patients with existing implants or restorations with excessive scatter were also excluded.

The CBCT was performed using the cs9300 instrument (60-90 kV, 2-15 mA; Carestream Health, New York, NY, USA). Each scan was evaluated in X, Y, and Z planes at a 0.09-mm slice interval.

Data collection

The SRP and root angulation to the osseous housing were evaluated in the cross-sectional images taken at the midpoint of each tooth parallel to the long axis. Classification was conducted during image assessment.

Buccal plate thickness was evaluated at 3 locations perpendicular to the periodontal ligament space of each tooth: 1 mm (measure I), 3 mm (measure II), and

5 mm (measure III) apical to the alveolar crest (Figure 1). The locations of dehiscence (DEH) and fenestration (FEN) defects of the buccal plate were recorded. The apical bone height of the maxillary premolars was also measured along the root long axis from the root apex toward the superior bone surface. The distance from the root apex to the inferior alveolar nerve or mental foramen along the root long axis was measured in mandibular premolars.

Classification and measurement were performed by a single calibrated examiner (Z.Y.L.). Intra-examiner reliability was determined by repeating 10% of the classifications and measurements. In addition, 10% of the classifications and measurements were independently repeated by a second examiner (W.M.Z.) to assess interexaminer reliability.

SRP and angulation classification

The relationship of the SRP to the osseous housing was categorized as follows (Figure 2): type B, closer to the buccal cortical plate including in contact with a portion

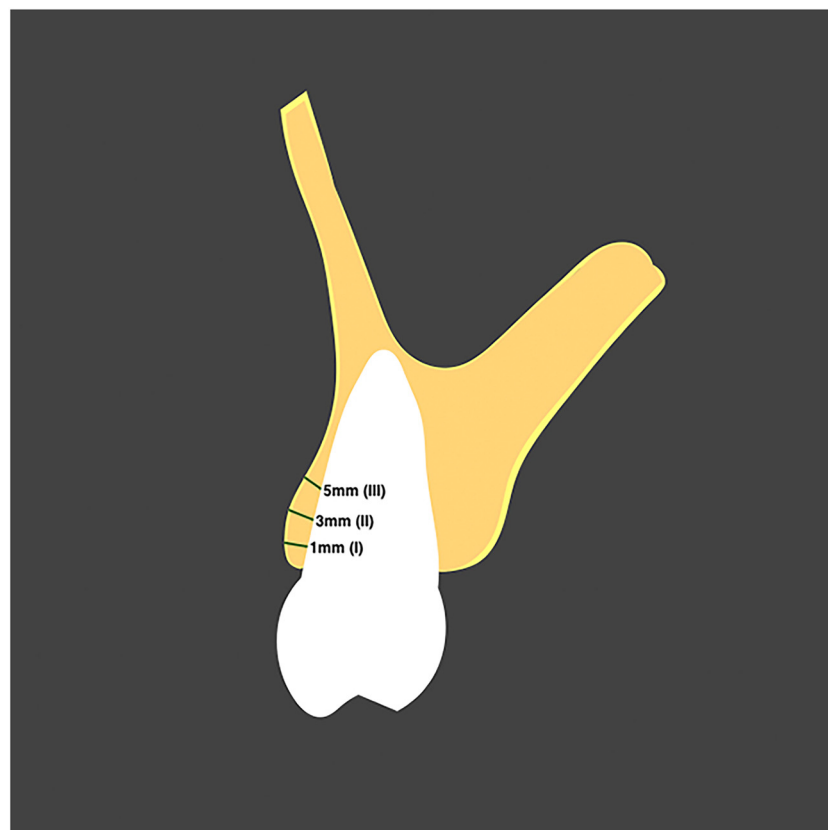


Fig. 1. Buccal plate thickness at three locations per tooth: 1 mm (measure I), 3 mm (measure II), and 5 mm (measure III) apical to the alveolar crest. In the case of a dehiscence defect, a line was drawn from the most coronal level of the palatal/lingual plate perpendicular to its long axis and defined as the presumptive zero point for buccal-plate measurement. Cone beam computed tomography images were processed to ensure the best geometric presentation for highly accurate measurement. In the axial plane, the arch-form selector tool was centered through the middle of the arch. In the sagittal plane, the volume was oriented to enable visualization of the entire root. An individual reference line for each tooth was created to generate the ideal coronal slice at the mid-root level apicocoronally.

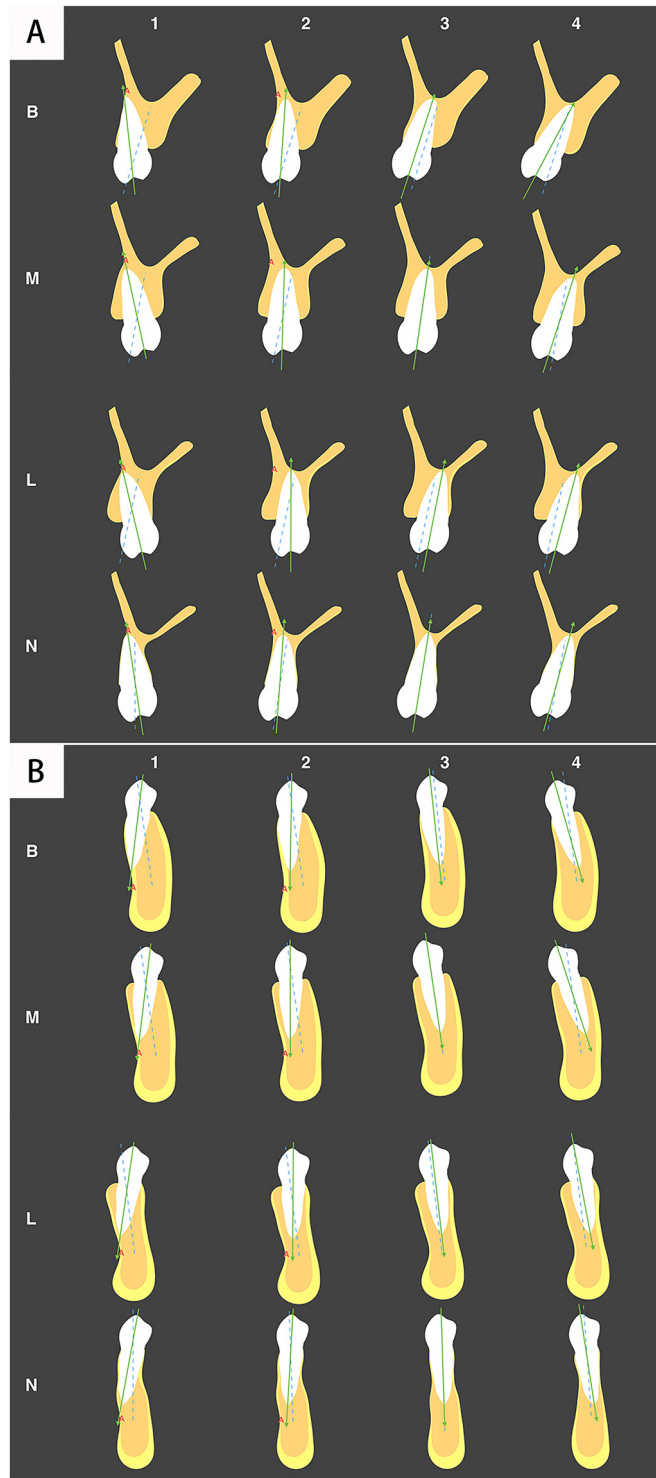


Fig. 2. Classification according to root position and angulation. The relationship of each sagittal root position to the osseous housing was categorized as the type B, M, L, or N; angulation was categorized as the class 1, 2, 3, or 4 in the (A) maxilla and (B) mandible. Solid line, root axis; dashed line, alveolar process centerline.

of the buccal cortex; type M, in the middle of the alveolar housing without engaging the buccal or palatal/lingual cortical plate; type L, closer to the palatal/lingual cortical plate including in contact with a portion of the palatal/lingual cortex; and type N, at least two-thirds of the root engaging both the buccal and palatal/lingual cortical plates. The angulation of the root long axis to the alveolar process was classified as follows (Figure 2): class 1, root axis angulated toward the buccal side with the long axis passing anterior to point A; class 2, root axis angulated toward the buccal side with the long axis passing posterior to point A; class 3, root axis angulated parallel to the alveolus; and class 4, root axis angulated toward the palatal/lingual side.

Statistical analysis

Statistical analysis was performed using SPSS software (SPSS, Inc., Chicago, IL, USA). Buccal plate thickness data exhibited a log-normal distribution, so the data were log-transformed for repeated-measures analysis of variance followed by post hoc Bonferroni correction for multiple comparisons.

RESULTS

In 55% of the repeated measurements by the same examiner, the differences were <0.1 mm, and in 96%, they were <0.2 mm. In 45% of the repeat measurements by 2 examiners, the differences were <0.1 mm, and in 90%, they were <0.2 mm. All of the repeated classifications were consistent.

For the frequency of each SRP category among the maxillary first premolars, 63.67%, 31%, 0%, and 5.33% were of types B, M, L, and N, respectively. The corresponding rates for the maxillary second premolars were 19.67%, 72.67%, 7.33%, and 0.33%, respectively. Among the mandibular first premolars, 90.67%, 8%, 0%, and 1.33% were of types B, M, L, and N, respectively. The corresponding rates for the mandibular second premolars were 78%, 22%, 0%, and 0%, respectively (Figure 3).

An analyses of both SRP type and angulation classification showed that for the maxillary first premolars, the incidence of type B1 was slightly lower than that of type B2. For the maxillary second premolars, the incidence of type M3 was 40.67%. For the mandibular first

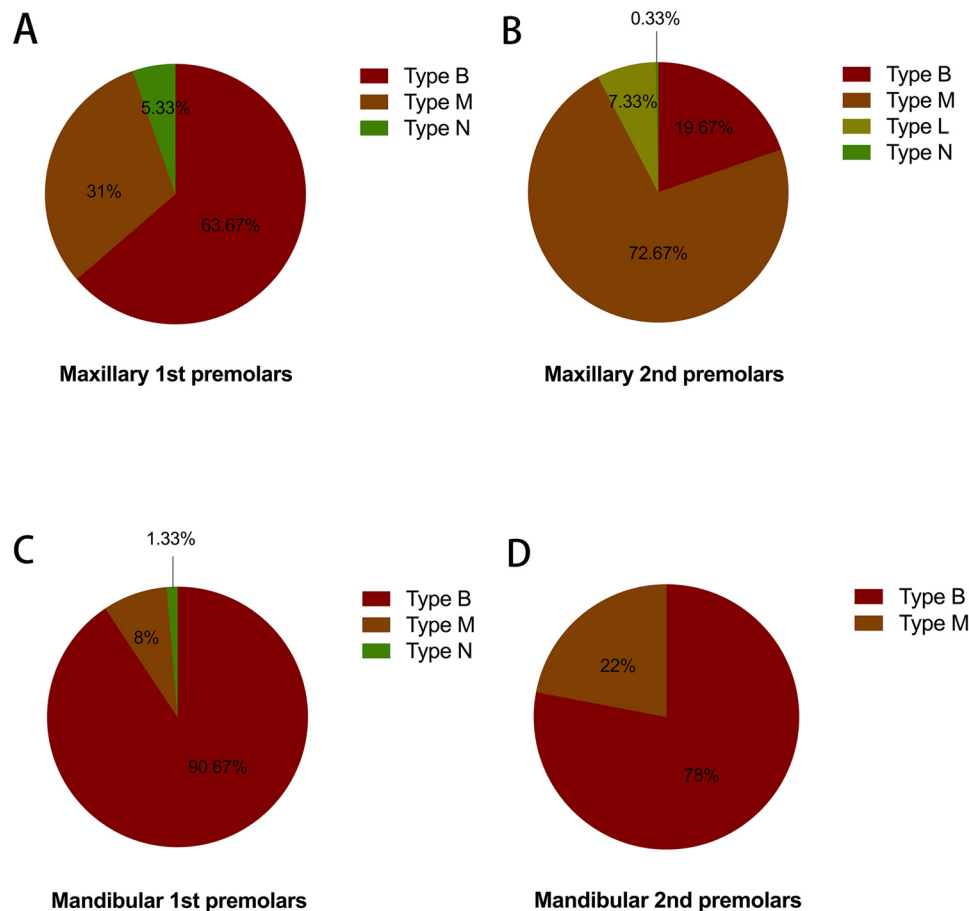


Fig. 3. Frequency distributions of sagittal root position types of the maxillary (A) first and (B) second premolars and mandibular (C) first and (D) second premolars.

premolars, the incidence of type B4 was 57%. For the mandibular second premolars, the incidence of type B3 (29%) was lower than that of type B4 (42.34%; Figure 4).

The position was a significant determinant of buccal plate thickness, with both arches demonstrating an increase in thickness from the first to the second premolars ($P < .001$; Figure 5). Buccal plate thickness at 1 mm apical to the alveolar crest level was < 1 mm in 55%, 21%, 95%, and 75.33% of the maxillary first and second premolars and mandibular first and second premolars, respectively. Only 8%, 0.33%, and 2.33% of the maxillary first and mandibular first and second premolars, respectively, had a buccal plate width of ≥ 2 mm (Figure 6).

Regarding apical bone height, 46% and 77.67% of the maxillary first and second premolars, respectively, had a distance < 4 mm from the root apex to the floor of the sinus (Figure 7), of which 12.67% and 41.67% of the maxillary first and second premolars, respectively, had a root apex close to the sinus floor (Figure 7). In the mandibular premolars,

12.33% and 20.33% of the mandibular first and second premolars, respectively, had a distance < 4 mm from the root apex to the inferior alveolar nerve or mental foramen (Figure 7). The incidence of DEH was 1%, 0%, 23%, and 3.33%, and that of FEN was 23%, 4%, 7.67%, and 2% for the maxillary first and second premolars and mandibular first and second premolars, respectively (Figure 8). In this study, 64% of the maxillary first premolars were double-rooted. Most of maxillary first premolars bifurcate into buccal root and palatal root in the mediate (50%) or apical (29.17%) root (Table 1). Almost all maxillary second premolars (98.67%) were single-rooted (Table 1). The root shape of maxillary first and second premolars was flat, in which the buccolingual dimension was larger than the mesiodistal dimension.

DISCUSSION

The IIP should aim for the maximum possible bone-to-implant contact to achieve good primary stability and promote osseointegration.¹⁰ The main drawback of IIP

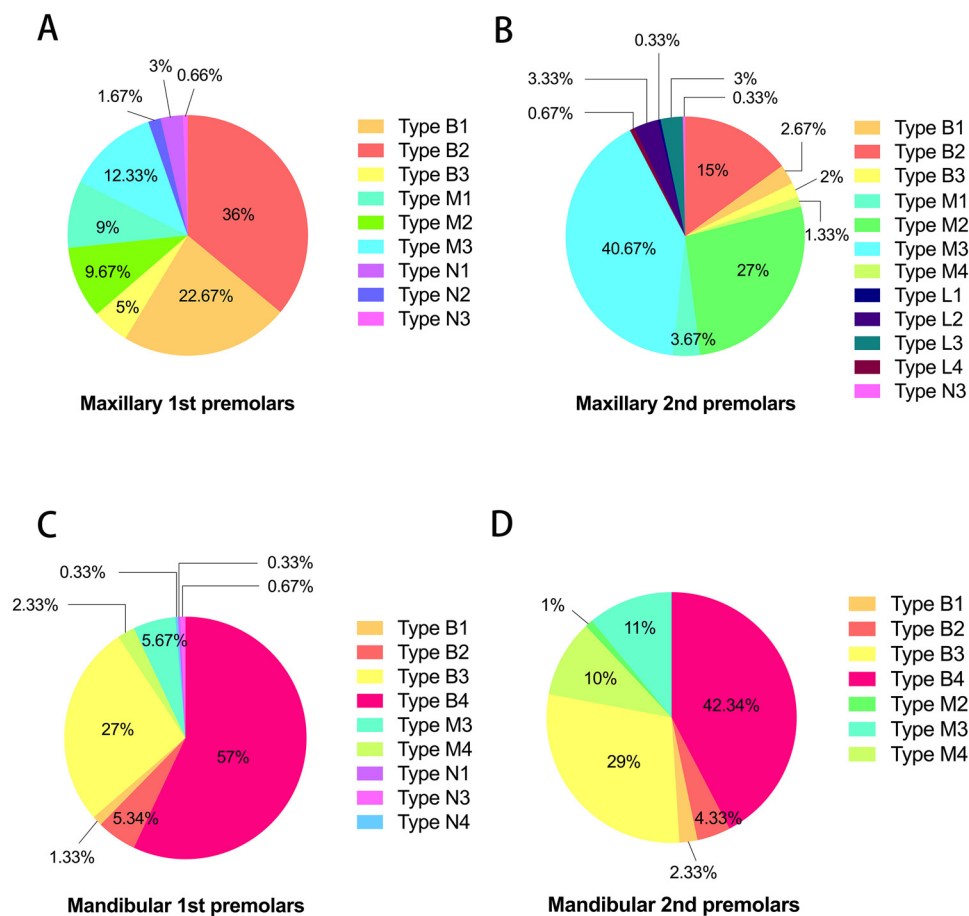


Fig. 4. Frequency distribution of combine sagittal root position types and angulation classifications of the maxillary (A) first and (B) second premolars and mandibular (C) first and (D) second premolars.

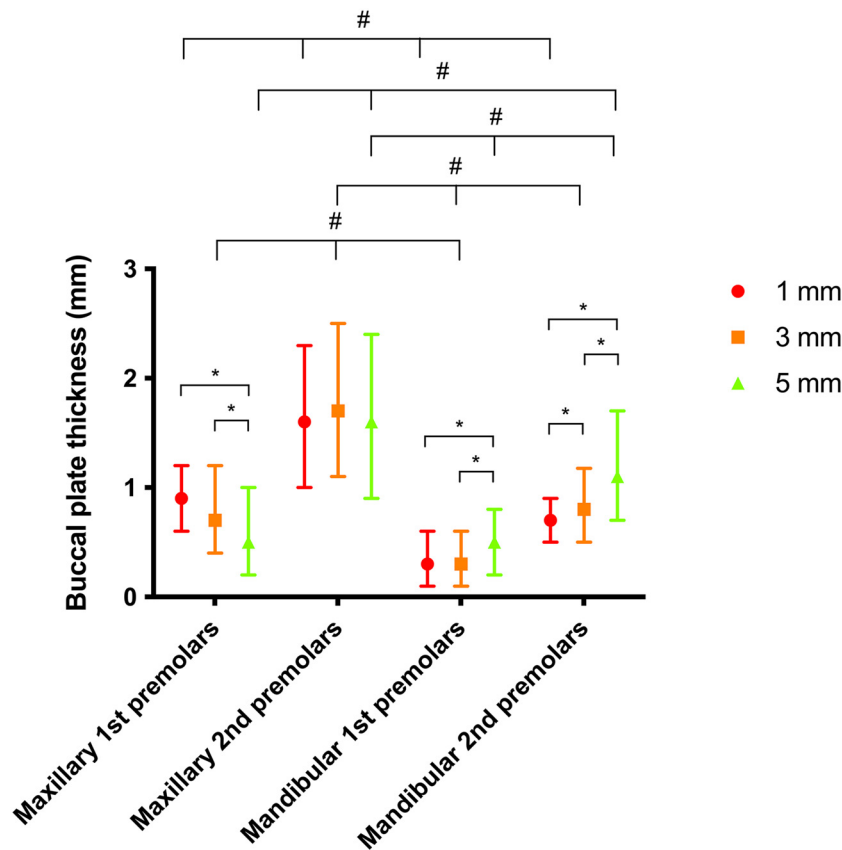


Fig. 5. Buccal-plate thickness of the maxillary and mandibular premolars at 1, 3, and 5 mm apical to the alveolar crest. Data are medians (P25, P75). In the maxillary first premolars, there was a significant decrease in buccal plate thickness coronally to apically along the root ($P < .05$). Conversely, in the mandible, buccal plate thickness increased significantly coronally to apically ($P < .05$). In both the maxilla and mandible at all measurement points, the first premolars were significantly thinner than the second premolars ($P < .001$). The mandibular second premolars were significantly thinner than those in the maxilla ($P < .001$). The data were log-transformed for repeated-measures analysis of variance. The overall P values of the comparisons on the maxillary first premolars, mandibular first premolars, and mandibular second premolars were $< .001$; $*P < .05$ after post hoc Bonferroni correction. The overall P values of the comparisons of different teeth at each location were $< .001$; $†P < .001$ after post hoc Bonferroni correction.

into the extraction sockets is the lack of predictability of the long-term soft tissue profile, particularly the buccal aspect. The mid-buccal recession of an immediate implant placed into a fresh extraction socket is reportedly 0.55 to 0.75 mm at 1 year of follow-up.^{11,12} Kohal

et al. showed that the pressure exerted by an inserted implant on the bony wall can result in microfractures, leading to crestal bone loss.¹³ The key to good long-term esthetic results is to avoid exerting pressure on the crestal bony wall, particularly on the buccal aspect.

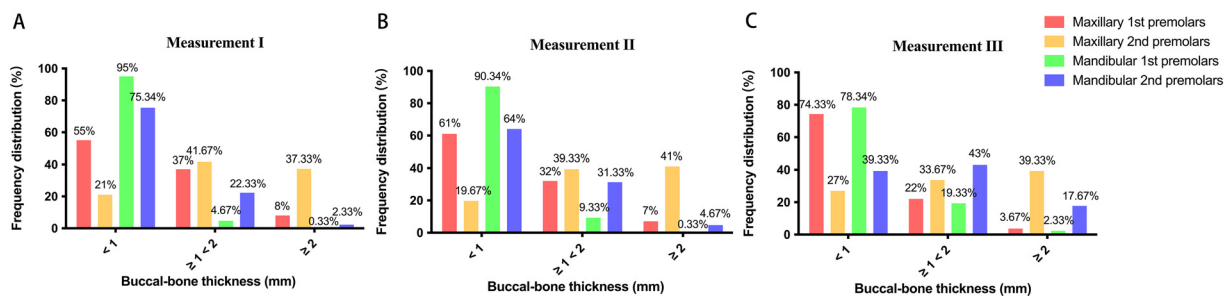


Fig. 6. Frequency distribution of buccal bone thickness at (A) 1, (B) 3, and (C) 5 mm apical to the bone crest.

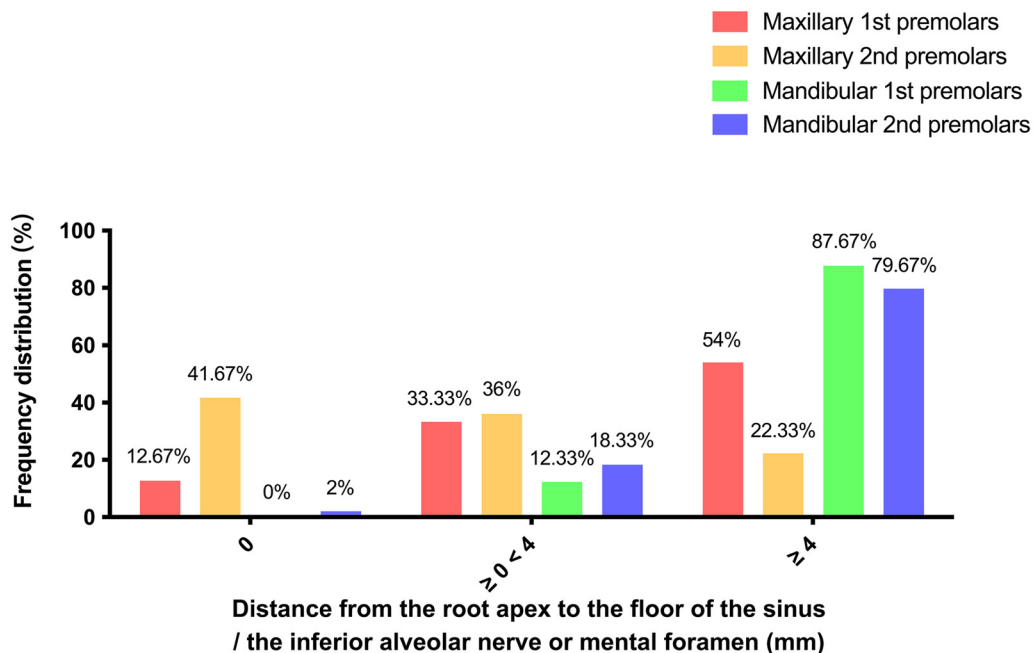


Fig. 7. Frequency distribution of the distance from the root apex to the floor of the sinus for maxillary premolars and from the root apex to the inferior alveolar nerve or mental foramen for mandibular premolars.

Therefore, the position at which an implant is placed is critical.

We evaluated and classified the SRP and angulation of premolars in relation to their osseous housing. The SRP and angulation types were categorized as level I to level III according to the difficulty achieving ideal esthetic results in IIP (Figure 9).

For level I types (types M2, M3, M4, L2, L3, and L4), an implant can be placed with the same position and angulation as the extraction socket without compromising the long-term esthetic outcome. This is

because a thick buccal bone provides more support to the overlying gingiva, minimizing mid-buccal recession and shrinkage of the overlying soft tissue and papillae. Because no modification of the drilling angle is required, a straight stock abutment can be used. These types are the most straightforward for both surgery and restoration at all levels. However, the amount of available bone beyond the apex of the extraction socket must be evaluated, because this is the primarily determinant of implant stability. Here, 46% of the maxillary first premolars and 77.67% of the maxillary

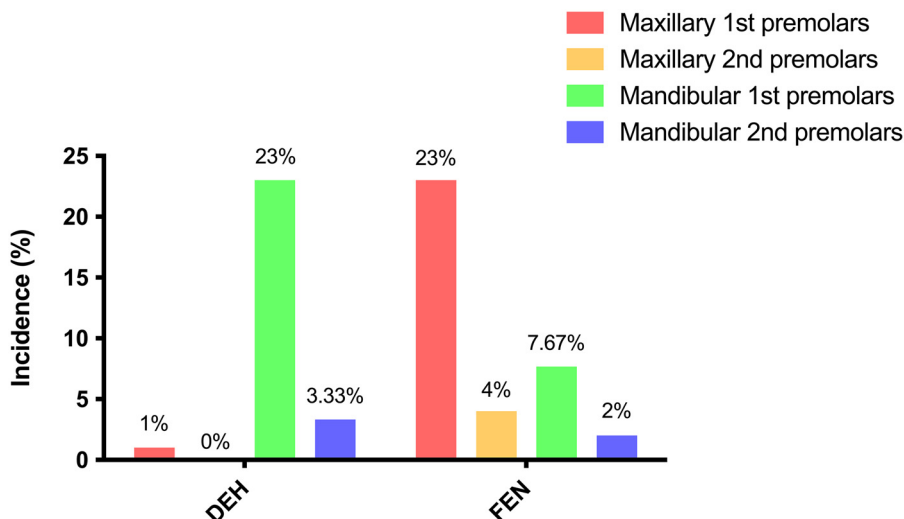


Fig. 8. Incidences of the dehiscence and fenestration in premolars. DEH, locations of dehiscence; FEN, fenestration.

Table 1. Distribution of the number and shape of the roots of maxillary premolars

	Single-rooted (%)	Double-rooted (%)			Total
		Root bifurcation			
		Coronal	Middle	Apical	
Maxillary first premolars	36.00	20.83	50.00	29.17	64.00
Maxillary second premolars	98.67	0.00	75.00	25.00	1.33

second premolars had a bone height of <4 mm; 12.33% of the mandibular first premolars and 20.33% of the mandibular second premolars had a distance from the root apex to the inferior alveolar nerve or mental foramen <4 mm. The IIP combined with maxillary sinus floor elevation or delayed implant placement is need in some such cases.¹⁴

Level II procedures (types B1, B2, B3, B4, M1, M2, L1, and L2) are more technically demanding. The position and angulation of the implant should be changed to avoid thinning of the buccal bone and to maintain the esthetic outcome over the long-term. The angle of the implant should be more palatal to avoid compressing or drilling the buccal bone, minimizing the risk of perforations and FENs. Because of the discrepancy between the implant angle and that of the original tooth, an angled abutment should be used to achieve good esthetics.

For a type B SRP, in which the root is closer to or in contact with the buccal cortical plate, a certain amount of bone is typically needed on the palatal/lingual aspect to achieve primary implant stability during IIP. The implant should be placed palatally/lingually to avoid drilling or compressing the buccal plate, minimizing the risk of thinning, FEN, or perforation of the buccal bone. In general, palatal implant engagement leaves

the buccal bone intact and results in a gap between the implant and the buccal bone.¹⁵ The implant-socket gap is typically filled with bone-grafting materials.¹⁶ In this study, 63.67% of the maxillary first premolars, 90.67% of the mandibular first premolars, and 78% of the mandibular second premolars had a type B SRP.

Types M1, M2, L1, and L2 have similar characteristics, including a thicker buccal plate. However, the root apices point toward the buccal side. If there is not enough bone present at the apical aspect, an attempt can be made by placing the implant both palatally and apically to avoid touching the buccal plate. An angled abutment is invariably needed for this purpose. The general recommendation for all level II cases is that the implants should be inserted with a modified position and angulation with reference to the extraction socket, as well as more palatally.

Level III types (types N1, N2, N3, and N4) are the contraindication for IIP. Following extraction, there is a limited amount of bone with which to achieve the required implant stability.¹⁷ The critical buccal plate thickness for reducing loss of buccal bone is ~2 mm.¹⁸⁻²⁰ In the majority of maxillary first premolars and mandibular premolars, the buccal plate thickness was <2 mm. The alveolar bone dimension become altered significantly at these sites.¹⁸⁻²⁰ To

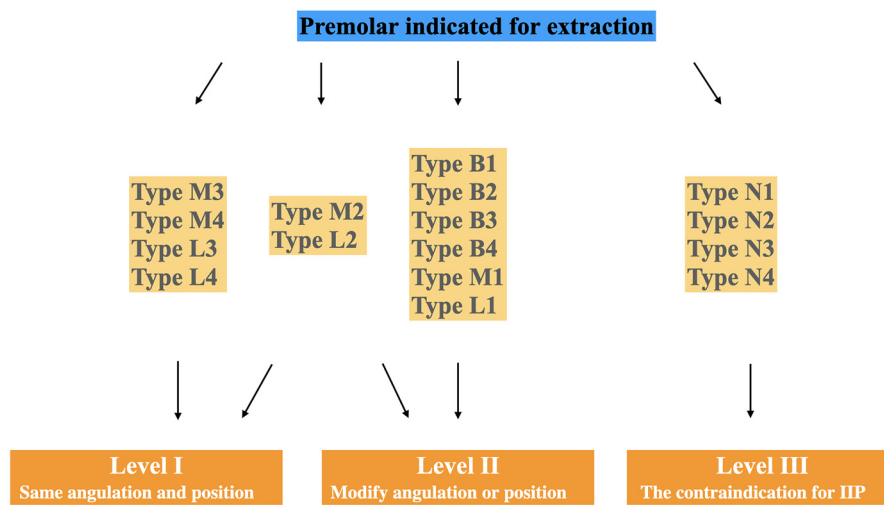


Fig. 9. Case level classified according to difficulty in achieving good long-term esthetic results for immediate implants.

increase the predictability of implant treatment, bone grafting is necessary at the time of tooth extraction or before or at the time of implant placement.²¹⁻²⁴ Such procedures promote long-term tissue stability. The role of CBCT in treatment planning for IIP should be emphasized.

CONCLUSIONS

In conclusion, bone availability in all dimensions should be considered to achieve good implant esthetics. The angulation and position of the original tooth should be determined in 3 dimensions during treatment planning. For level I cases, inserting the implant with the same angulation as the socket using a standard drilling protocol is straightforward. For level II cases, the implant position and angulation should be changed to a more palatal aspect. It is recommended to first use a round bur to create a step at the palatal aspect of the socket before using a straight drill to ensure that the hardness of the cortical bone and natural contour of the socket do not result in erroneous drilling parallel to the apical long axis. The implant should be inserted with good primary stability, without exerting pressure on the buccal wall or causing perforation in the apical region. To prevent pressure on the buccal bone, the operator can leave a gap between the implant surface and the buccal bone, as long as primary stability is not compromised. The gap can be treated with grafting materials to promote osteointegration and soft tissue healing.²⁵⁻²⁷ The implant shoulder should be optimally placed in terms of the depth and buccal-palatal dimension. For level III cases, a protocol can enhance the long-term outcome by grafting or preserving the alveolar ridge before implant placement. However, this category is not appropriate for cases with bone depression on the lingula side of the mandibular premolars. A potential limitation of this study was a degree of false positives (false DEH or FEN) with CBCT. The mesial/distal root width may also influence immediate implant stability. A suitable implant type of customized length and diameter at the apical, mid-body, and coronal levels results in good primary stability and esthetics.

We categorized the SRP types and angulations of the premolars and established objective clinical guidelines to prevent complications in IIP. Our classification system will improve interdisciplinary communication during the planning of IIP for premolars.

ACKNOWLEDGMENT

The authors thank the faculty of the Oral Radiology Clinic for help with the execution of this project. The article has been posted as a preprint on the Research Square.

FUNDING

This work was supported by the National Natural Science Foundation of China (81800976) and the National Key Research and Development Program (2019YFB1404801).

DISCLOSURE

none.

REFERENCES

- Lang NP, Pun L, Lau KY, Li KY, Wong MC. A systematic review on survival and success rates of implants placed immediately into fresh extraction sockets after at least 1 year. *Clin Oral Implants Res.* 2012;23:39-46.
- Kan JY, Roe P, Rungcharassaeng K, et al. Classification of sagittal root position in relation to the anterior maxillary osseous housing for immediate implant placement: a cone beam computed tomography study. *Int J Oral Maxillofac Implants.* 2011;26:873-876.
- Furhauser R, Florescu D, Benesch T, Haas R, Mailath G, Watzek G. Evaluation of soft tissue around single-tooth implant crowns: the pink esthetic score. *Clin Oral Implants Res.* 2005;16:639-644.
- Kaabi N, Zerei M, Mhamdi T, M'Barek R. Immediate implant placement decision making. *Clin Oral Implants Res.* 2018;29:432.
- Huynh-Ba G, Pjetursson BE, Sanz M, et al. Analysis of the socket bone wall dimensions in the upper maxilla in relation to immediate implant placement. *Clin Oral Implants Res.* 2010;21:37-42.
- Braut V, Bornstein MM, Belser U, Buser D. Thickness of the anterior maxillary facial bone wall—a retrospective radiographic study using cone beam computed tomography. *Int J Periodont Rest.* 2011;31:125-131.
- Braut V, Bornstein MM, Lauber R, Buser D. Bone dimensions in the posterior mandible: a retrospective radiographic study using cone beam computed tomography. Part 1—analysis of dentate sites. *Int J Periodont Res.* 2012;32:175-184.
- Januario AL, Duarte WR, Barriviera M, Mesti JC, Araujo MG, Lindhe J. Dimension of the facial bone wall in the anterior maxilla: a cone-beam computed tomography study. *Clin Oral Implants Res.* 2011;22:1168-1171.
- Nowzari H, Molayem S, Chiu CH, Rich SK. Cone beam computed tomographic measurement of maxillary central incisors to determine prevalence of facial alveolar bone width ≥ 2 mm. *Clin Implant Dent R.* 2012;14:595-602.
- Wilson TG Jr, Schenk R, Buser D, et al. Implants placed in immediate extraction sites: a report of histologic and histometric analyses of human biopsies. *Int J Oral Maxillofac Implants.* 1998;13:333-341.
- Kan JY, Rungcharassaeng K, Lozada J. Immediate placement and provisionalization of maxillary anterior single implants: 1-year prospective study. *Int J Oral Maxillofac Implants.* 2003;18:31-39.
- Cornelini R, Cangini F, Covani U, et al. Immediate restoration of implants placed into fresh extraction sockets for single-tooth replacement: a prospective clinical study. *Int J Periodontics Restorative Dent.* 2005;25:439-447.
- Kohal RJ, Hurzeler MB, Mota LF, et al. Custom-made root analogue titanium implants placed into extraction sockets: an experimental study in monkeys. *Clin Oral Implants Res.* 1997;8:386-392.
- Liu H, Liu R, Wang M, Yang J. Immediate implant placement combined with maxillary sinus floor elevation utilizing the trans-alveolar approach and nonsubmerged healing for failing teeth in

- the maxillary molar area: A randomized controlled trial clinical study with one-year follow-up. *Clin Implant Dent R.* 2019;21:462-472.
15. Kan JYK, Rungcharassaeng K, Deflorian M, Weinstein T, Wang HL, Testori T. Immediate implant placement and provisionalization of maxillary anterior single implants. *Periodontol 2000.* 2018;77:197-212.
 16. Kuchler U, Chappuis V, Gruber R, Lang NP, Salvi GE. Immediate implant placement with simultaneous guided bone regeneration in the esthetic zone: 10-year clinical and radiographic outcomes. *Clin Oral Implants Res.* 2016;27:253-257.
 17. McAllister BS, Haghighat K. Bone augmentation techniques. *J Periodontol.* 2007;78:377-396.
 18. Spray JR, Black CG, Morris HF, Ochi S. The influence of bone thickness on facial marginal bone response: stage 1 placement through stage 2 uncovering. *Ann Periodontol.* 2000;5:119-128.
 19. Belser U, Martin W, Jung R, et al. *ITI Treatment Guide, Volume 1: Implant Therapy in the Esthetic Zone. Single-tooth Replacements.* Batavia, IL: Quintessence Publishing Co. Ltd.; 2007.
 20. Qahash M, Susin C, Polimeni G, Hall J, Wikesjo UM. Bone healing dynamics at buccal peri-implant sites. *Clin Oral Implants Res.* 2008;19:166-172.
 21. Donos MRN. Guided bone regeneration: biological principle and therapeutic applications. *Clin Oral Implants Res.* 2010;21:567-576.
 22. Wang RE, Lang NP. Ridge preservation after tooth extraction. *Clin Oral Implants Res.* 2012;23:147-156.
 23. Mardas N, Trullenque-Eriksson A, MacBeth N, Petrie A, Donos N. Does ridge preservation following tooth extraction improve implant treatment outcomes: a systematic review: group 4: therapeutic concepts & methods. *Clin Oral Implants Res.* 2015;26:180-201.
 24. Canellas JVDS, da Costa RC, Breves RC, et al. Tomographic and histomorphometric evaluation of socket healing after tooth extraction using leukocyte- and platelet-rich fibrin: a randomized, single-blind, controlled clinical trial. *J Craniomaxillofac Surg.* 2020;48:24-32.
 25. Wilson TG Jr.. Guided tissue regeneration around dental implants in immediate and recent extraction sites: initial observations. *Int J Periodontics Restorative Dent.* 1992;12:185-193.
 26. Lang NP, Bragger U, Hammerle CH, et al. Immediate transmucosal implants using the principle of guided tissue regeneration. I. Rationale, clinical procedures and 30-month results. *Clin Oral Implants Res.* 1994;5:154-163.
 27. Ferrus J, Cecchinato D, Pjetursson EB, Lang NP, Sanz M, Lindhe J. Factors influencing ridge alterations following immediate implant placement into extraction sockets. *Clin Oral Implants Res.* 2010;21:22-29.