

# Vascularized Free Fibular Flap in Oral and Maxillofacial Reconstruction: A 20-year Experience at a Single Institution Using 2640 Flaps

Yi-Fan Kang, DDS, Xiao-Feng Shan, MD, Lei Zhang, MD, Chi Mao, MD, Yang Wang, MD, Jie Zhang, MD, Yi Zhang, MD, Chuan-Bin Guo, MD, Guang-Yan Yu, MD, Zhi-Gang Cai, DMD, and Xin Peng, MD

**Background:** This retrospective study reviewed all patients who underwent oral and maxillofacial reconstruction with fibular flaps in the last 2 decades at a single hospital.

**Materials and Methods:** We reviewed all patients with fibular flaps from 1999 to 2018. The following data were collected: sex; age; reconstruction region; diagnosis; the number of days spent in the hospital after surgery; time spent using a tourniquet for harvesting a fibula flap; vessels at the recipient site; the prevalence of unplanned reoperations; the prevalence of flap failure; history of preoperative radiotherapy; virtual surgical planning; segments of the fibula.

**Results:** In total, 2640 patients were included. The mean age was 45.5 years. The most prevalent region of reconstruction was the mandible (n = 2347, 88.9%). The most common diagnosis was squamous cell carcinoma (n = 1057, 40.0%). The mean number of days spent in the hospital after surgery decreased year-by-year from 18.3 days to 10.4 days. The first choice of recipient artery was the facial artery (n = 1643, 62.2%) and that of the recipient vein was the external jugular vein (n = 1196, 45.3%).

The prevalence of surgical success was 97.6%. Prevalence of unplanned reoperations was 7.5%.

**Conclusions:** The fibular flap was a good choice for oral and maxillofacial bony reconstruction in most cases.

**Key Words:** Complication, free fibular flap, oral and maxillofacial, reconstruction, vessel crisis

(*J Craniofac Surg* 2023;34: 1459–1463)

The vascularized free fibular flap was introduced first by Hidalgo in 1989 for mandible reconstruction.<sup>1</sup> With advancements in reconstructive microsurgery, the use of the fibular flap to reconstruct oral and maxillofacial bony defects has become very popular at many centers and institutions. Several donor sites are available to provide a vascularized bone graft for oral and maxillofacial reconstruction (eg, iliac flap, scapular flap, radius flap). However, the fibular flap is the first choice for most cases because of the long vascular pedicle, a wide diameter of peroneal vessels, types and volumes of tissues, and suitability for dental implants.<sup>2</sup>

At Peking University School and Hospital of Stomatology (PKUSS), the first surgical procedure to obtain a free fibular flap for oral and maxillofacial reconstruction was started at the end of 1998, and only 1 case was completed in 1998. Since 1999, an increasing number of fibular flaps have been used gradually for different defects in head and neck regions.

We reviewed cases using a fibular flap at PKUSS and our experience of fibular-flap reconstructions in the last 2 decades. We undertook this project to ascertain how the work was undertaken at PKUSS and what must be done in the future to improve the prevalence of success of using fibular flaps.

## MATERIALS AND METHODS

### Patients

From January 1999 to December 2018, all patients who underwent oral and maxillofacial bony reconstruction with free fibular flaps in the Department of Oral and Maxillofacial Surgery of PKUSS were reviewed. Patients with complete medical records were included in this retrospective study.

### Data

The following data were collected: sex; age; reconstruction region; diagnosis; the number of days spent in the hospital after surgery; time spent using a tourniquet for harvesting a fibula flap; vessels at the recipient site; the prevalence of unplanned

From the Department of Oral and Maxillofacial Surgery, Peking University School and Hospital of Stomatology; National Center of Stomatology; National Clinical Research Center for Oral Diseases; National Engineering Laboratory for Digital and Material Technology of Stomatology; Beijing Key Laboratory of Digital Stomatology; Research Center of Engineering and Technology for Computerized Dentistry Ministry of Health; and National Medical Products Administration (NMPA) Key Laboratory for Dental Materials, Beijing, PR China.

Received December 16, 2021.

Accepted for publication October 10, 2022.

Address correspondence and reprint requests to Zhi-Gang Cai, DMD (c2013xs@163.com), and Xin Peng, MD (pxpengxin@263.net), Department of Oral and Maxillofacial Surgery, Peking University School and Hospital of Stomatology, 22# Zhongguancun South Avenue, Haidian District, Beijing 100081, PR China.

Y.-F.K. and X.-F.S. contributed equally.

Z.-G.C. and X.P. equally contributed to this work and should be considered as co-corresponding authors.

This work was supported by the National Program for Multidisciplinary Cooperative Treatment on Major Diseases (PKUSSNMP-202015).

The authors report no conflicts of interest.

**Supplemental Digital Content is available for this article. Direct URL citations appear in the printed text and are provided in the HTML and PDF versions of this article on the journal's website, [www.jcraniofacialsurgery.com](http://www.jcraniofacialsurgery.com).**

Copyright © 2023 by Mutaz B. Habal, MD

ISSN: 1049-2275

DOI: 10.1097/SCS.00000000000009193

reoperations; the prevalence of flap failure; history of preoperative radiotherapy; virtual surgical planning; segments of the fibula. Data were collected using Excel 2019 (Microsoft).

## Statistical Analyses

Data were analyzed using SPSS 26.0 (IBM). The Pearson correlation coefficient was employed to investigate the correlation between the number of cases each year and the prevalence of success, as well as the number of cases and prevalence of unplanned reoperations. The  $\chi^2$  test was used to investigate the prevalence of vascular crisis and flap failure between patients who had received preoperative radiotherapy and patients who had not, the difference of vein crisis between the external jugular vein and other veins, and the difference of vein crisis between 1 vein and 2 veins.  $P < 0.05$  was considered significant.

## RESULTS

In total, 2640 patients (1637 males and 1003 females) were included in this retrospective study. The mean age was 45.5 (range, 8–82) years. The most common region of reconstruction for the fibular flap was the mandible ( $n = 2347$ , 88.9%), followed by the maxilla ( $n = 289$ , 10.9%), and both the maxilla and mandible ( $n = 4$ , 0.2%). And 4 typical cases are shown in Figure 1. The relationship between the reconstruction region and age is shown in Figure 2.

The most common diagnosis for patients who underwent reconstruction using a fibular flap is shown in Supplementary Digital Content 1, Table 1, <http://links.lww.com/SCS/E757>. The mean number of days spent in the hospital after surgery decreased year-by-year from 18.3 days to 10.4 days. The mean duration of time spent using a tourniquet for harvesting a flap was 59.0 min. The relationship between the mean duration of time spent using a tourniquet for harvesting a flap and age is shown in Figure 3.

The first choice of recipient artery was the facial artery ( $n = 1643$ , 62.2%), followed by the superior thyroid artery ( $n = 655$ , 24.8%), lingual artery ( $n = 159$ , 6.0%), external carotid artery ( $n = 133$ , 5.0%) and other arteries ( $n = 9$ , 0.3%). There

were 41 cases in which the recipient artery was not recorded. The first choice of recipient vein was the external jugular vein ( $n = 1196$ , 45.3%), followed by the facial vein ( $n = 731$ , 27.7%), branches of the internal jugular vein ( $n = 557$ , 21.1%), internal jugular vein ( $n = 110$ , 4.2%) and other veins ( $n = 2$ , 0.1%). There were 44 cases in which the recipient vein was not recorded.

There were 198 unplanned reoperations (7.5%), of which the most common reason was vessel crisis ( $n = 138$ , 69.7%) (Supplementary Digital Content 1, Table 2, <http://links.lww.com/SCS/E757>). Of the reoperations caused by the vascular crisis, 18 cases were a misdiagnosis that vasospasm and thrombosis were not found, and the condition of the anastomosis vessel was “good”. The relationship between the prevalence of unplanned reoperations and age is shown in Figure 4. In total, the number of patients who had an artery crisis was 34, and failure was noted in 28 cases. The number of patients who had a vein crisis was 86, and failure was noted in 35 cases. Necrosis of the skin island occurred in 4 patients; the skin island was removed and only the bone flap remained. The prevalence of success of fibular flaps from 1999 to 2018 was 97.6%. The relationship between the prevalence of success of fibular flaps and age is shown in Figure 5.

The data for calculating the Pearson correlation coefficient was divided into 2 groups according to age. The data for group A were from 1999 to 2009. The data for group B were from 2010 to 2018. The correlation between the number of cases and prevalence of success was positive in group A ( $r = 0.49$ ,  $P < 0.05$ ), but it was not relevant in group B ( $P > 0.05$ ). The correlation between the number of cases and prevalence of an unplanned reoperation was negative in group A ( $r = -0.59$ ,  $P < 0.05$ ), but it was positive in group B ( $r = 0.42$ ,  $P < 0.05$ ).

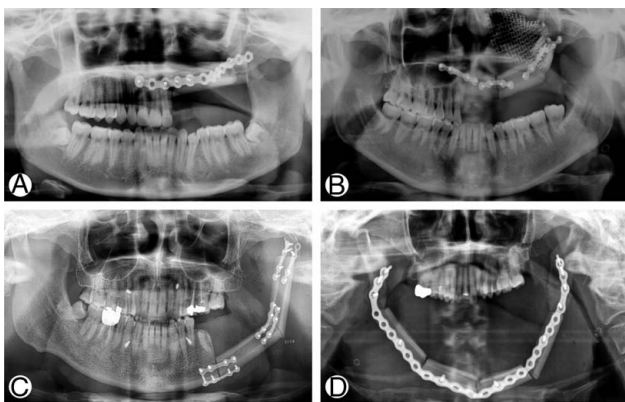
Preoperative radiotherapy was received by 214 patients. Eight of 214 patients had flap failures. However, the prevalence of vascular crisis and flap failure was not significantly different between patients who had received preoperative radiotherapy and the patients who had not ( $P > 0.05$ ). There were 37 vein crisis cases and 1159 normal cases using the external jugular vein as the recipient vein. And there were 49 vein crisis cases and 1351 normal cases using other veins as recipient vein. There was no significant difference between 2 groups ( $P > 0.05$ ). There were 74 vein crisis cases and 2152 normal cases using 1-vein anastomosis. And there were 12 vein crisis cases and 358 normal cases using 2-vein anastomosis. There was no significant difference between 2 groups ( $P > 0.05$ ).

After 2010, a computer-assisted navigation system was introduced in our hospital. In the last 9 years, the jaws of 185 patients were reconstructed using virtual surgical planning and other methods of digital surgery. Fibular flaps were shaped from 1 to 5 segments. The most common number of fibular flap segments was 2 ( $n = 1416$ , 53.6%), followed by 3 segments ( $n = 847$ , 32.1%), 1 segment ( $n = 237$ , 9.0%), 4 segments ( $n = 72$ , 2.7%) and 5 segments ( $n = 2$ , 0.1%). There were 66 cases in which the shaping condition was not recorded.

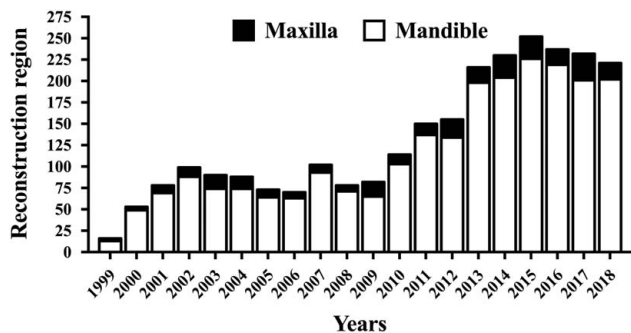
## DISCUSSION

With the development of microsurgery at PKUSS, >2600 fibular flaps have been harvested in the last 2 decades. During this time, we have made progress in the harvesting of fibular flaps and reconstruction of head and neck regions from <20 fibular flaps per year to >200 fibular flaps per year. Moreover, the number of surgeons who can harvest a fibular flap has increased.

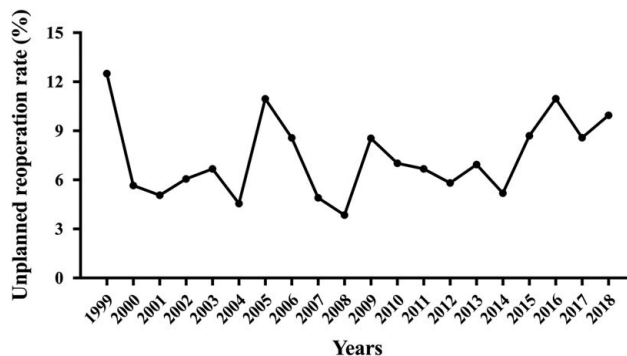
Several factors can influence the choice of flap: extent of the defect, comorbidities, patient lifestyle, and nature of the



**FIGURE 1.** Typical cases: A, A 19-year-old female was treated for left maxillary ameloblastoma. There was a Brown class II defect after maxillectomy. A one-segment fibular flap was performed for reconstruction. B, A 33-year-old female was diagnosed as left maxillary myxoma. There was a Brown class III defect after maxillectomy. Prebent individual titanium mesh was used for orbital floor reconstruction and a 3-segment fibular flap was used for maxillary reconstruction. C, A 45-year-old male was performed mandibulectomy because of left mandibular ameloblastoma. The left condyle was saved, a 2-segment fibular flap was used for mandibular bony and ramus reconstruction. D, A 44-year-old female was treated for osteosarcoma. The defect was from the left angle to the right angle. A 4-segment fibular flap was performed for reconstruction.



**FIGURE 2.** The number of fibular flaps for maxillary and mandibular reconstruction at PKUSS from 1999 to 2018. PKUSS indicates Peking University School and Hospital of Stomatology.



**FIGURE 4.** Prevalence of unplanned reoperations at PKUSS from 1999 to 2018. PKUSS indicates Peking University School and Hospital of Stomatology.

disease.<sup>3</sup> The surgical team must make the best choice based on the individual status of the patient.<sup>4</sup> The fibular flap has been the “gold standard” for maxillary and mandibular reconstruction in recent years. Almost half of the free flaps were fibular flaps used for oral and maxillofacial reconstruction in PKUSS each year.<sup>5</sup> This situation is very similar to that of another famous center, Shanghai Ninth People’s Hospital, which carries out oral and maxillofacial surgery in China.<sup>6</sup>

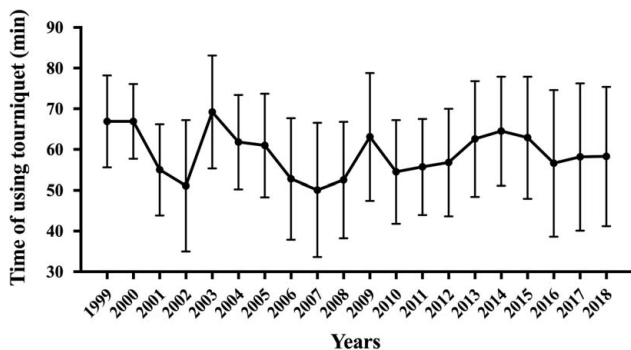
For maxillary reconstruction, the age of the patient, defect size, and the desire for dental rehabilitation have important roles with regard to flap choice. A soft-tissue flap is a good option for a patient who might have economic issues and who does not seek dental rehabilitation.<sup>7</sup> If the defect is large and a lot of tissue is needed to fill dead space, a fibular flap might not be the first choice. Moreover, the age of the patient may be a major factor: younger patients have a stronger desire for treatment and higher postoperative quality of life than older patients. One study from PKUSS showed that patients who underwent reconstruction using a fibular flap were the youngest of all the patients who had total maxillary reconstruction.<sup>8</sup>

For mandibular reconstruction, the fibular flap is the “workhorse” flap. The mandible is the only movable bony structure in the head and neck region. Hence, bony reconstruction is crucial for improving the patient’s quality of life. Comparing the data in Figure 2, the number of fibular flaps for maxillary reconstruction in 2017 was less than the number for mandibular reconstruction in 2000. However, the choice of flap for mandibular reconstruction showed some changes in recent years at PKUSS. Dental rehabilitation became an increasingly important part of functional reconstruction. An insufficient

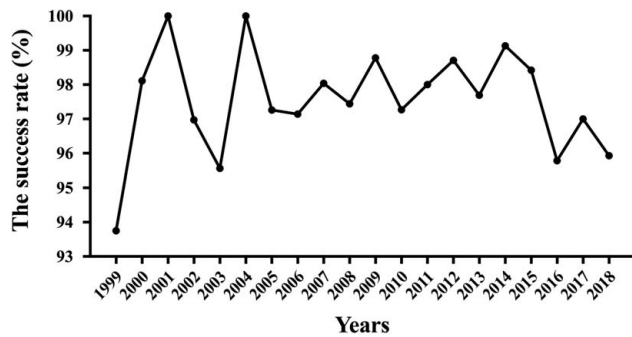
height of fibular bone was the main reason for limiting its use for dental rehabilitation. We tried the double-barrel method,<sup>9</sup> distraction osteogenesis<sup>10</sup> and using a fibular flap with a nonvascularized fibular bone graft,<sup>11</sup> but these methods led to longer procedures or a higher prevalence of complications.<sup>12</sup> With the development of digital surgical methods, the iliac flap has sufficient bone volume and has become more suitable for dental implantation. Nowadays, if the mandibular defect is <10 cm, the tumor is benign, or the patient requires dental rehabilitation, the iliac flap might be the first choice for mandibular reconstruction.

The prevalence of unplanned reoperations is a well-known standard for the assessment of surgical quality. It is also a very important reference for the quality of medical treatment.<sup>13</sup> The mean prevalence of unplanned reoperations at PKUSS was 7.5%. The prevalence of unplanned reoperations is related to the difficulty of the procedure, patient age, and the surgeon’s skill.<sup>13</sup> Using a fibular flap for oral and maxillofacial reconstruction is very complicated, which may explain the high prevalence of unplanned reoperations noted in the present study. The prevalence of unplanned reoperations showed a “staged” downward trend (Fig. 5). Stage 1 was from 1999 to 2004, Stage 2 was from 2005 to 2008, Stage 3 was from 2009 to 2014, and Stage 4 was from 2015 to 2018. This trend was very similar to the trend of the duration of tourniquet use, and we postulate that it had a relationship with young surgeons joining the surgical team. After a period of clinical training, the prevalence of unplanned reoperations decreased. Choi and colleagues showed that unplanned reoperations have negative effects on oncological outcomes, especially for malignant tumors.<sup>14</sup> No surgical procedure is without risk, but sufficient clinical training and meticulous surgical treatment are crucial in reducing the risk of unplanned reoperations.

Flap failure is a crucial issue with regard to free flaps. A vessel crisis can occur and lead to vascular thrombosis or vasospasm. The prevalence of success using a free flap can depend on the microsurgical method, choice of recipient vessel, and history of preoperative radiotherapy. The prevalence of success after using a free fibular flap was 97.6% from 1999 to 2018 at PKUSS. In a previous study at PKUSS using free flaps, the prevalence of success using total free flaps was 97.0%, and that of fibular flaps was the highest among the other flap types used.<sup>5</sup> The facial artery and superior thyroid artery were preferred, but the facial artery was the first choice in most cases at PKUSS. With regard to the recipient vein, the external jugular vein was the first choice because of its constant anatomic position and sufficiently long length. However, the external jugular vein is at the surface of the sternocleidomastoid muscle, and it might be compressed



**FIGURE 3.** Mean duration of time spent using a tourniquet to harvest flaps at PKUSS from 1999 to 2018. PKUSS indicates Peking University School and Hospital of Stomatology.



**FIGURE 5.** Prevalence of success of maxillary reconstruction at PKUSS from 1999 to 2018. PKUSS indicates Peking University School and Hospital of Stomatology.

postoperatively. The internal jugular vein is also a good choice for microsurgery (especially the facial vein). The rule for choosing the recipient vein is that the diameter of the vessel should be as wide as possible.<sup>5</sup>

The correlation between the number of cases and prevalence of success was positive from 1999 to 2009 but was not relevant from 2010 to 2018. We postulate that this result was due to the surgeon needing a period of time to learn a new skill. We also found a negative correlation between the number of cases and prevalence of unplanned reoperations from 1999 to 2009, and a positive correlation from 2010 to 2018. This increasing trend between the number of cases and prevalence of unplanned reoperations from 2010 to 2018 was unusual and may have been because: (i) we tried to treat more complicated problems after a long period of training; (ii) young surgeons joined the microsurgery team.

Some studies have demonstrated that preoperative radiotherapy might cause the failure of free flaps, which might make vascular walls more fragile.<sup>5,6,15</sup> In the present study, preoperative radiotherapy was received by 214 patients. However, the prevalence of vascular crisis and flap failure was not significantly different for patients who received preoperative radiotherapy and those who did not. In our experience, preoperative radiotherapy is 1 of the risk factors for free-flap failure. When we created the reconstruction plan, we considered the history of radiotherapy. Thus, the condition of the recipient area was evaluated for patients chosen to undergo reconstruction with a free fibular flap. This bias in choice might have led to the prevalence of flap failure showing no significant difference between patients who received preoperative radiotherapy and those who did not.

In the present study, fibular bones were shaped in 2 or 3 segments in most cases. Moreover, fibular bones were shaped in 4 segments in 72 patients and 5 segments in 2 cases. It is hard to imagine how difficult this would be without the aid of computer-assisted surgery (CAS). CAS has become a new standard in the reconstruction of large and complex defects in oral and maxillofacial regions.<sup>16</sup> Several advantages of CAS have been documented: shorter surgical procedures, reduction in the size of donor-site defects, and better postoperative functional and esthetic outcomes.<sup>17–19</sup> In our experience, although some procedures became easier with the help of CAS, the training and knowledge of surgeons were as important as before using CAS. This was because the surgeon needed to decide the length of the fibula, the angle between each fibular segment, and the direction of vessels during virtual surgical planning preoperatively instead of intraoperatively. Besides, we prefer to use miniplates for fixation, which are more flexible than a reconstruction plate and

elicit the same outcomes.<sup>20</sup> In our clinical practice, the fibular flap can be shaped after the pedicle division, which is more flexible and convenient for operation, especially for multi-segment shaping. However, the ischemia time should be kept within 1 hour to avoid related complications.

In 2 decades, progress had also been made in perioperative management, especially in postoperative nursing (Supplementary Digital Content 1, Table 3, <http://links.lww.com/SCS/E757>). From 1999 to 2005, patients needed to stay in the hospital > 2 weeks (maybe almost 3 wk) after surgery. From 2006 to 2013, the mean number of days spent in the hospital after surgery decreased to 11 to 13 days. From 2014 to the present day, the mean number of days spent in the hospital after surgery was 11 days. The mean number of days spent in the hospital after surgery is related to changes in the concept of treatment using free flaps. Early studies showed that most episodes of vascular crisis occurred in the first 3 days after surgery.<sup>21,22</sup> The position of the head and neck after surgery is very important for flap success in the oral and maxillofacial region. Restriction of movements of the head and neck was applied strictly. From 1999 to 2012, patients were told to lay on the bed with restriction of head and neck movements for 5 days postoperatively, and off-bed activity was allowed on the day 7. From 2013 to 2017, the number of lay-on-the-bed days was reduced to 3 days, and off-bed activity was allowed on the day 5. Recent studies have shown that 78.3% to 82.3% of episodes of vascular crisis occur <24 h after surgery.<sup>23,24</sup> Thus, from 2018 to the present day, we recommended sitting up 2 days and off-bed activity 3 days after surgery, and the prevalence of flap success has not changed.<sup>25</sup>

In conclusion, a fibular flap was a good choice for oral and maxillofacial bony reconstruction in most cases at PKUSS. The high prevalence of success and use of CAS could elicit satisfactory outcomes for the surgeon and patient. Sufficient clinical training and knowledge are the foundations to reduce the prevalence of unplanned reoperations.

## REFERENCES

- Hidalgo DA. Fibula free flap: a new method of mandible reconstruction. *Plast Reconstr Surg* 1989;84:71–79
- Frodel JL Jr, Funk GF, Capper DT, et al. Osseointegrated implants: a comparative study of bone thickness in four vascularized bone flaps. *Plast Reconstr Surg* 1993;92:449–455; discussion 56–8
- Mucke T, Holzle F, Loeffelbein DJ, et al. Maxillary reconstruction using microvascular free flaps. *Oral Surg Oral Med Oral Pathol Oral Radiol Endodontology* 2011;111:51–57
- Andrades P, Militsakh O, Hanasono MM, et al. Current strategies in reconstruction of maxillectomy defects. *Arch Otolaryngol Head Neck Surg* 2011;137:806–812
- Zhou W, Zhang WB, Yu Y, et al. Risk factors for free flap failure: a retrospective analysis of 881 free flaps for head and neck defect reconstruction. *Int J Oral Maxillofac Surg* 2017;46:941–945
- Lou C, Yang X, Hu L, et al. Oromandibular reconstruction using microvascularized bone flap: report of 1038 cases from a single institution. *Int J Oral Maxillofac Surg* 2019;48:1001–1008
- Yang Y, Li PJ, Shuai T, et al. Cost analysis of oral and maxillofacial free flap reconstruction for patients at an institution in China. *Int J Oral Maxillofac Surg* 2019;48:590–596
- Yu S, Wang Y, Mao C, et al. Classification and reconstruction of 1107 cases of maxillary defects. *J Peking Univ Health Sci* 2015;3: 509–513; (in Chinese)
- Horiuchi K, Hattori A, Inada I, et al. Mandibular reconstruction using the double barrel fibular graft. *Microsurgery* 1995;16:450–454
- Nocini PF, Wangerin K, Albanese M, et al. Vertical distraction of a free vascularized fibula flap in a reconstructed hemimandible: case report. *J Craniomaxillofac Surg* 2000;28:20–24

11. Lee JH, Kim MJ, Choi WS, et al. Concomitant reconstruction of mandibular basal and alveolar bone with a free fibular flap. *Int J Oral Maxillofac Surg* 2004;33:150–156
12. Chang YM, Wallace CG, Hsu YM, et al. Outcome of osseointegrated dental implants in double-barrel and vertically distracted fibula osteoseptocutaneous free flaps for segmental mandibular defect reconstruction. *Plast Reconstr Surg* 2014;134:1033–1043
13. Zhao ZF, Hao J, He Q, et al. Unplanned reoperations in oral and maxillofacial surgery. *J Oral Maxillofac Surg* 2019;77:135.e1–135.e5
14. Choi N, Park SI, Kim H, et al. The impact of unplanned reoperations in head and neck cancer surgery on survival. *Oral Oncol* 2018;83:38–45
15. Benatar MJ, Dassonville O, Chamorey E, et al. Impact of preoperative radiotherapy on head and neck free flap reconstruction: A report on 429 cases. *J Plastic Reconstr Aesth Surg* 2013;66:478–482
16. Raith S, Rauen A, Mohlhenrich SC, et al. Introduction of an algorithm for planning of autologous fibular transfer in mandibular reconstruction based on individual bone curvatures. *Int J Med Robot* 2018;14:e1894
17. Zhang WB, Wang Y, Liu XJ, et al. Reconstruction of maxillary defects with free fibula flap assisted by computer techniques. *J Craniomaxillofac Surg* 2015;43:630–636
18. Shan XF, Chen HM, Liang J, et al. Surgical navigation-assisted mandibular reconstruction with fibula flaps. *Int J Oral Maxillofac Surg* 2016;45:448–453
19. Monaco C, Stranix JT, Avraham T, et al. Evolution of surgical techniques for mandibular reconstruction using free fibula flaps: The next generation. *Head Neck* 2016;38(Suppl 1):E2066–E2073
20. Liu SP, Cai ZG, Zhang J, et al. Stability and complications of miniplates for mandibular reconstruction with a fibular graft: outcomes for 544 patients. *Br J Oral Maxillofac Surg* 2016;54:496–500
21. Kroll SS, Schusterman MA, Reece GP, et al. Timing of pedicle thrombosis and flap loss after free-tissue transfer. *Plast Reconstr Surg* 1996;98:1230–1233
22. Devine JC, Potter LA, Magennis P, et al. Flap monitoring after head and neck reconstruction: evaluating an observation protocol. *J Wound Care* 2001;10:525–529
23. Bui DT, Cordeiro PG, Hu QY, et al. Free flap reexploration: indications, treatment, and outcomes in 1193 free flaps. *Plast Reconstr Surg* 2007;119:2092–2100
24. Chen KT, Mardini S, Chuang DCC, et al. Timing of presentation of the first signs of vascular compromise dictates the salvage outcome of free flap transfers. *Plast Reconstr Surg* 2007;120:187–195
25. Yang Y, Wu HY, Wei L, et al. Improvement of the patient early mobilization protocol after oral and maxillofacial free flap reconstruction surgery. *J Craniomaxillofac Surg* 2020;48:43–48

Downloaded from by BhDMf5ePHKbH4TTImqenVA+ipjWIBvonhO60EigidiLrLzSPu+hlUpvK5dms8 on 06/30/2023



**Congratulations**

to our active ed. bord member dr Gabriel Santiago/ wow an MBA from Wharton

Now a Penn graduate and an active member of the neuroplastic society